Dark -Field Microscopic Analysis on the Blood of 1,006 Symptomatic Persons After Anti-COVID mRNA Injections from Pfizer/BioNtech or Moderna

New large published study from Italy confirms extreme blood abnormalities and self-assembly nanostructures

Ana Maria Mihalcea, MD, PhD
Aug 29

53 30

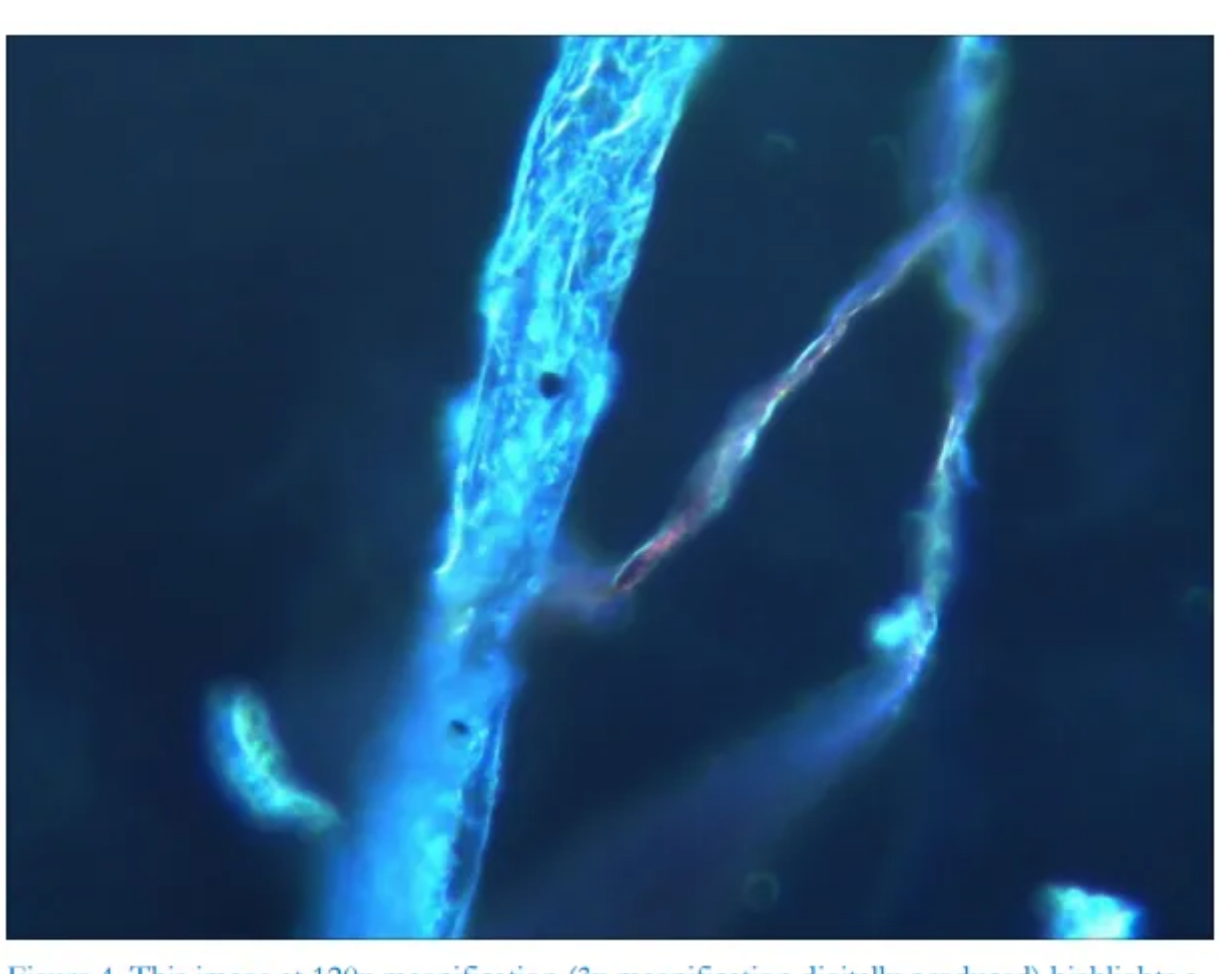

Figure 4. This image at 120x magnification (3x magnification digitally produced) highlights a typical self-aggregating structuring in fibro/tubular mode.

This recently published study from Italy once again confirms self assembly nanostructures in the blood of C19 injected people. The authors correlate the blood findings with the symptoms of the affected. For example this case was discussed:

> This individual is a male of 33 years, who formerly was an athlete, apparently healthy before inoculation with an mRNA Pfizer injection. One month after receiving the first dose of the Pfizer "vaccine", he showed marked asthenia, a constant gravitational headache (i.e., one sensitive to the position and movements of his head and body such that the pain was increased by movement of the head up or down). The headaches were unresponsive to common pain killers. Diffuse rheumatic arthralgia with dyspnea on exertion were noted.

This was his blood finding:

Thanks for reading Dr. Ana's Newsletter!
Subscribe for free to receive new posts and support my work.

derekcbishop@hushmail.com ✓



The authors show that these self-assembly nanoparticles conglomerate to create massive structures. These provide the basis for extensive clotting and abnormal blood flow.

Figure 6. The sharper and larger image on the left seems to suggest the power of the exogenous particles introduced into the blood of mRNA injection recipients to assemble themselves into massive structures: we can see in both (a) and (b) at 120x magnification evidence of what appear to be lamellar configurations similar to agglomerations occurring in a field of forces pulling colloidal particles in the plasma together. The relative bulk of the particle conglobate can be easily estimated by comparison with the erythrocytes at the periphery of the much larger mass. It was also measured accurately at 113.91μm by 139.99μm (see the hatch mark green lines in b) using the Delta-Pix Software as shown in the computer screen shot at the right.

Here are further self assembly nanostructures:

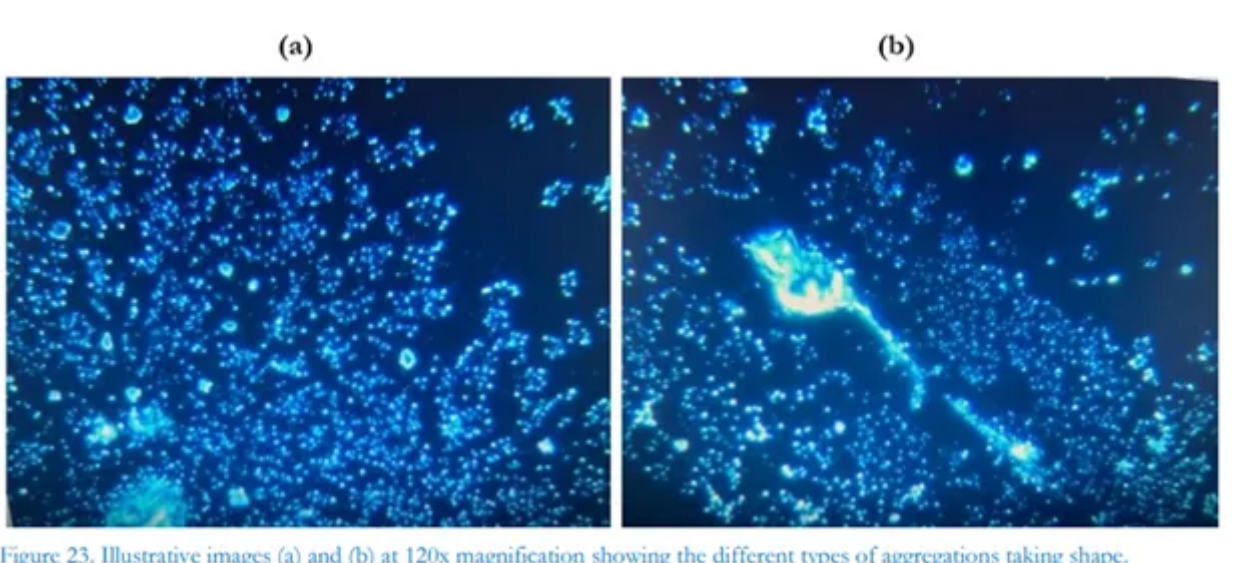

Figure 23. Illustrative images (a) and (b) at 120x magnification showing the different types of aggregations taking shape.

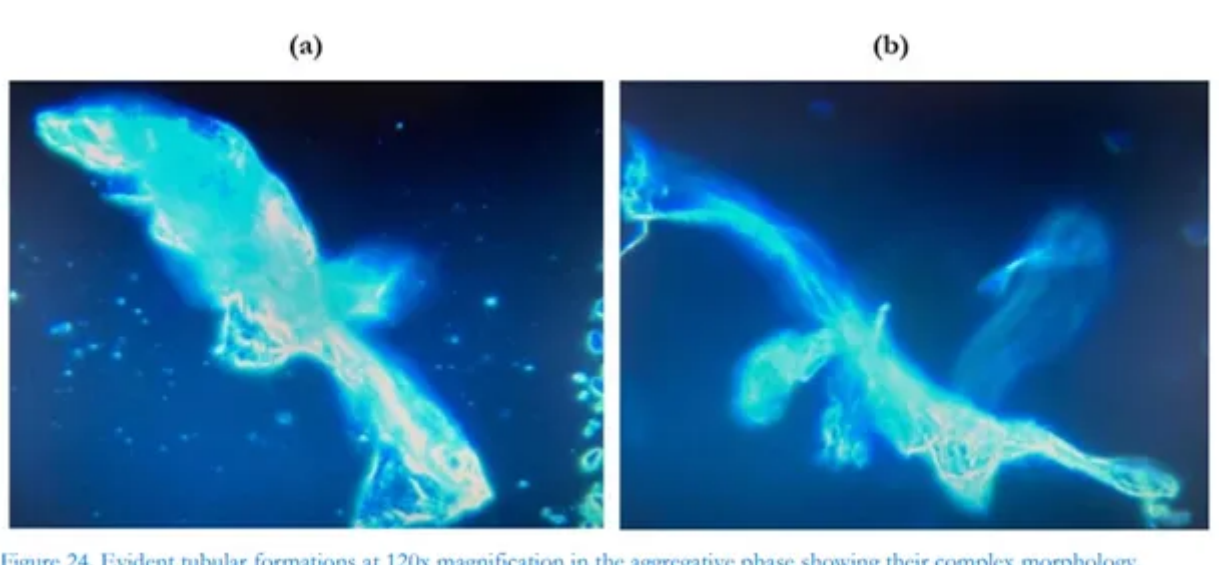

Figure 24. Evident tubular formations at 120x magnification in the aggregative phase showing their complex morphology.

The authors conclude:

> "In conclusion, such abrupt changes as we have documented in the peripheral blood profile of 948 patients have never been observed after inoculation by any vaccines in the past according to our clinical experience.
>
> The sudden transition, usually at the time of a second mRNA injection, from a state of perfect normalcy to a pathological one, with accompanying hemolysis, visible packing and stacking of red blood cells in conjunction with the formation of gigantic conglomerate foreign structures, some of them appearing as graphene-family super-structures, is unprecedented.
>
> "Such phenomena have never been seen before after any "vaccination" of the past."
>
> In our collective experience, and in our shared professional opinion, the large quantity of particles in the blood of mRNA injection recipients is incompatible with normal blood flow especially at the level of the capillaries."

Here is the full article:

Benzi+cipelli+et+al
11.6MB · PDF File
Read now

This is mounting evidence in addition to what already has been published with similar findings that I listed here:

> Dr. Ana's Newsletter
>
> **Alarming New Report from Working Group of Vaccine Analysis in Germany and Other Countries**
>
> From the report: The COVID-19 vaccination programs must be stopped immediately The German Working Group for COVID Vaccine Analysis has made its initial findings publicly available in a wide-ranging report:Thanks for reading Dr. Ana's Newsletter! Subscribe for free to receive new posts and support my work…
>
> Read more
>
> 21 days ago · 95 likes · 58 comments · Ana Maria Mihalcea, MD, PhD

In my view, the discovery of novel screening tools that can be used for early detection of potentially life threatening blood clots is imperative.

These are exactly the blood findings described by my colleague, Felipe Reitz. More than ever, I believe that the evaluation if Computerized Thermography Imaging could be an early screening tool is imperative. I wrote about this here, and please look at our video interview.

> Dr. Ana's Newsletter
>
> **Computerized Thermographic Imaging and Live Blood Analysis Post C19 Injection**
>
> In this interview with Brazilian biologist and medical researcher Felipe Reitz we discuss his findings of live blood analysis and thermographic Imaging of C19 injected individuals. A thermogram is a regional temperature map of the surface of a part of the body, which is obtained by an infrared sensing device. This measures radiant heat and subcutaneous…
>
> Read more
>
> 7 days ago · 139 likes · 157 comments · Ana Maria Mihalcea, MD, PhD

Here is an example of a 23 year old asymptomatic athlete, obtained by Felipe Reitz, with abnormal thermogram who had a deep vein thrombosis confirmed via Doppler Ultrasound. He had similar abnormal live blood analysis with self-assembly nanostructures as the Italian researchers found and published in this article.

Summary:

If these structures are magnetic, MRI's and other imaging studies should not be performed as they may cause tissue damage due to excitation of the magnetic particles. This could cause further harm and injury to the injected. Full body Ultrasound imaging is difficult to perform, but full body Computerized Thermography could be done safely.

Dangerously, many allopathic physicians treating vax injuries are in complete denial of the self assembly nanostructures as a cause for pathology. I wonder how much evidence they need to take this seriously?

We must find the safest way of screening for asymptomatic blood clotting, and clearly live blood analysis is a tool that all treating physicians should urgently familiarize themselves with. D-Dimers are valuable, but may not be able to pick up all blood clotting. Dr. Charles Hoffe stated that 62% of his C19 injected patients had an elevated D-Dimer, but all live blood analysis in injected patients are abnormal. The sensitivity of D-Dimer testing may be suboptimal.

Further correlation studies in C19 injected people with evaluation of live blood analysis, D-Dimer testing, Computerized Thermography Imaging and if abnormal, Doppler Ultrasound confirmation need to happen urgently. We need to screen every athlete, every pilot, every medical professional - and in fact every person who got theses shots. If we do, we may be able to prevent sudden adult or child death syndrome.

Above all, the dangerous shots need to be stopped immediately and everyone responsible, held accountable.

Thanks for reading Dr. Ana's Newsletter!
Subscribe for free to receive new posts and support my work.

derekcbishop@hushmail.com ✓

53 likes

53 30

30 Comments

Write a comment…

jacquelyn sauriol Writes Substack won't let me get rid o… Aug 29 Liked by Ana Maria Mihalcea, MD, PhD

With the summer I have been looking alot at the condition of peoples skin and look of their tissues; I swear I can see it has changed, more ruddy looking throughout. As an herbalist, I have made and used food grade Witch Hazel and Willow tinctures for normal clots and blood health. But since these clots are so dense and non biological, it seems, I do wonder if there is anything that will address it. I also used Burdock Root Tea in great quanity to get through Covid itself from 11/19-2/2020. Burdock has quercitin and inulin and so it was very helpful for keeping my blood sugar up when my appetite was wonky. I felt like I had a cross between whooping cough and mono and lost 10% body wt which came back only very slowly. I have to hand it to them, perfect way to do up a genocide, so many different bits of virus, a relative smorgasbord you could say. Thanks for your very clear writing Dr. Ana- best from Oregon

6 Reply Collapse •••

11 replies

Patti Kay Wooldridge RN BSN Aug 29 Liked by Ana Maria Mihalcea, MD, PhD

Dr Ana your article on darkfield finding particles in blood confirms what I have been seeing with my microscope. I have bright field and darkfield. I also see a lot of Roulough in blood samples. I had a hunch last year that unvaccinated but exposed to C19 in 2020 blood might look the same as a vaxed persons. I was prompted to get a good microscope last year and confirmed it! I'm seeing similar particles and parasites. I've sent your article to Think Tank members that I know. Thank you for the work you are doing!

Patti

4 Reply Collapse •••

5 replies

28 more comments…

Top New Community

Alarming New Report from Working Group of Vaccine Analysis in Germany and Other Countries
Vaccines Must Be Stopped Immediately!
ANA MARIA MIHALCEA, MD, PHD AUG 8 106 63

Computerized Thermographic Imaging and Live Blood Analysis Post C19 Injection
Shocking New Images - Stop The Shots Now!
ANA MARIA MIHALCEA, MD, PHD AUG 22 146 167

"Shedding" – Understanding Self spreading vaccines in the Setting of Novel mRNA Technology
Discussing Observations and Sounding the Alarm - What is the Truth?
ANA MARIA MIHALCEA, MD, PHD JUN 29 42 49

See all ›

© 2022 Ana Mihalcea, MD, PhD · Privacy · Terms · Collection notice
Publish on Substack Get the app
Substack is the home for great writing