URGENT: JUST LISTED BENIAN TO SEND THE EXPOSE TO YOUR FAMILY. 90 minutes currently suspended on your account. Buzzsprout thinks we only delete on your account. But it every single one of you emailing this suspension at Jeremy Scott and Duane the Dude to keep going for another year and could remove this annoying banner...

Dismiss

Search

Search ...

Translate

Select Language | Powered by Google Translate

Support The Expose!

The Expose! relies solely on your support. We don't have any backers, we don't take any money from any organisations, we don't take any ads. We only rely on donations to keep us living during a time when corporate media is deeply dishonest.

DONATE

Follow Us

Recent Posts

- Royal Palace Kill a Man + Pure of Heart Kill a Woman – Ancient Egyptian Ritual
- Australian Supermarket Receipts, Numbers and Antibodies
- Australian Supermarket Receipts Prove A Huge Jump In Sales

Canadian Researchers Find Carbon Nanotech and Thulium in Moderna and Pfizer Covid Injections

By Expose Staff on May 28, 2022 | 0 Comments

Listen to this article now

00:00 06:15

Print PDF Email

Office receiving electron microscopic images of elements contained in the Covid Pfizer and Moderna injections, Dr. Daniel Nagase revealed that, amongst, the contents of the Pfizer and Moderna "vaccines" show no signs of biological materials, including mRNA or DNA.

Dr. Nagase is a Canadian emergency room doctor who was just on involuntary leave for successfully treating patients with ivermectin, and who is now being investigated by his medical board. He has since been moving through Alberta and British Columbia, presenting his research and his case. Now back in Canada, Nagase said he has also been "learning a lot about the legal system" while reviewing the medical records of people whose family members have died as a result of the "vaccines."

In the slides below Dr. Nagase discusses his findings with Melanie Rodier, a reporter with the Western Standard.

The Expose! reports the facts the mainstream refuse to: Let's not lose touch, subscribe today to receive the latest news from The Expose! in your inbox...

Email Address

SUBSCRIBE

Follow The Expose! on Telegram
Join The Expose's Telegram Discussion Group

Dr. Nagase was able to obtain samples of both Pfizer and Moderna Covid injections. "Unfortunately, I couldn't get Johnson & Johnson," he said. "I'm still trying to get that, because I think that it has been unemployed for up to two months." I don't know exactly how long they've been left unrefrigerated," he said.

Initially, the research group looked at these Moderna and Pfizer samples under a regular microscope. Although there were a lot of very interesting images, they were unable to be conclusive about what they were looking. So, they used the electron microscope to determine what elements the "vaccines" contained.

"You would expect to see carbon, oxygen, nitrogen, and phosphorus—all the things you would normally see in a protein," he said. The team of researchers found carbon in abundance, but none of the samples contained nitrogen or phosphorus.

"It was spectroscopy that didn't show any nitrogen or phosphorus. So, if these complex shapes—that rectangle with all the dots arranged in a grid—were the result of some kind of biological process, it would have to be a biological process that doesn't involve any nitrogen or phosphorus. It would have to be something very, very strange, which is a virus, plant or animal, to make up of proteins that contain nitrogen, carbon, oxygen, and phosphorus."

And electron microscopy revealed the same, no nitrogen and no phosphorus.

"[This] particular Moderna sample from somewhere in Canada has no RNA in it. It has no mRNA. Or if there is mRNA, it is overwhelmed by a disappointed other being left unrefrigerated for anywhere from two months to six months."

Dr. Nagase presented a half with the bugs growing out of it found inside a Moderna sample. "This shape, the ball with the bugs growing out of it, for some reason has aluminium in it. And I can say with certainty that this isn't a neutral space or some other type of biological contamination, because bugs only living in a carbon environment, they're not going to grow out of phosphorus, which would indicate something contaminating it of origin. So, this thing that's growing is not biological.

Found in a Moderna Covid "vaccine" sample

This confirms what Polish biologist and geologist Dr Franc Zalewski discovered last year about what he called a "scientific" or a "living" and was later called a "nanocolonyal" by Professor Dr Carlos Calaveras.

"It seems to have ever lived and three bugs. I did some tests and here are the results: aluminium, titanium and carbon," Dr. Zalewski said. He established that the head of the "thing" was made of aluminium.

A surprising and new discovery that Dr. Nagase and the researchers made was an unusual element found in the mysterious vaccine. Rhodium, a rare, little-known element found in a Pfizer sample.

Found in a Pfizer Covid "vaccine" sample

According to Wikipedia, we retrieve 20 April 2022, "Rhodium is the second-most abundant of the platinum group metals. It is a very rare, silvery white, hard, and chemically inert metal. It has one stable isotope, Rh, and occurs in high grade ores only. Rhodium is used as the catalyst agent in petrolate 9-ray devices, and in some solid-state lasers. It has no significant biological role and is not known to be toxic. It is also a very rare element in the Earth's crust, with an average of 0.001 parts per million, which, when ever earth, ... The principal sources today are the ion exchange chain of southern Ontario.

Dr. Nagase and the researchers found a variety of shapes and structures inside the "vaccine" samples they tested – crystals, chips, strands, bulbs, spherens, fibres and balls with legs growing out of them – he have photocopies, which is every different forms." he said.

"They all seem to be made predominantly out of carbon and oxygen and they seem in both the Moderna and Pfizer samples. So, it's very, very, very, very, very, very, very, very, very, very, very, carbon-oxygen crystals seem to be taking metaphorical forms and crystalline forms. And in the Pfizer sample, ... seem to only be forming fibres and crystals.

"So again, what are all these things doing? Carbon-oxygen can certainly be a sign that there's graphene in it but how do they make graphene take all these different shapes: from spherens to fibres to crystals. And so I'm not aware of with my scientific knowledge."

"I don't know know if this carbon technology, this carbon nanotechnology, is in every batch or is it just in a few batches, or what it means. I don't know. I don't know what it means. I don't know what it's for. I'm just putting a slightly different lens on it and I'm saying that in many countries around the world being given different injections, and we're being observed to see, 'well, who dies the fastest?' Who gets sick the fastest? Who gets the most side effects from experimental ingredients being unidiscriminately and without disclosure being given to people?"

Click on the image below to watch Dr. Nagase's presentation on Rumble.

Western Standard: Dr. Nagase reviews images from Covid vaccines, shows no "elements of life" – Dr. Daniel Nagase (20:14 video)

The transcript of Dr. Nagase's presentation, including images of his slides, is attached below.

Transcript Dr. Daniel Nagase

Download

We urgently need your support to keep The Expose online.

We rely solely on your support to help fund our investigative reports. If you find our work useful please help us to keep doing it by supporting us today.

It's secure, quick, and easy...

Please choose your preferred option below to support us:

ONE TIME DONATION

MONTHLY SUBSCRIPTION

BUY US A COFFEE

DONATE CRYPTO

Send Bitcoin

1Ee7Bwwq8ZvTNdGzzNNm1WFZ2Ta4cTNcPX

Paste this address into your Bitcoin Wallet.

Send Monero

Follow Daily Expose on Telegram

Follow Daily Expose on Rumble

Follow Daily Expose on Telegram

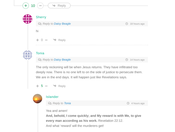

Follow Daily Expose on Telegram

WE'RE BEING CENSORED AS PLEASE SHARE THIS ARTICLE

Share

LIKE THIS:

Like 0 bloggers like this.

RELATED

Categories: Breaking News, World News

Tags: Canada, Canada News

Covid Lies: Australian Government Vaccines, Boosters and Antibodies

Dear Andrew Neil... UK Gov. Report admits 18.6 million people have been adversely affected by the Covid-19 Vaccine & there are now 30.5 million "Vaccine Refusers" ►

3

Social Rating

Subscribe ▾ Login

Join the discussion

B I U S ⊟ ⊟ ⊟

Sonia
Reply to Kate Kerr
2 minutes ago

I forgot to add that,
Also the superior cause of a fibrosis has called that anything genetically modified forbids to Gut grown statements signs.
That ruling is essentially worldwide.

Tyghe
Kate Kerr
2 minutes ago

It seems a great shame not to have used fresh samples that had not possibly degraded, especially if they were not kept at the right temperature. Is it really that difficult to get samples of these tissues?

Reply

Gordon P
10 days ago

Here I told you so. Spike protein was a diversion all along. Magnetic protein?! Carbon and oxygen – graphene oxide.

Reply

Tonia
2 months ago

Anyone can go on their local shopping centre or even cemetery and turn on their blue tooth & scan new devices & you'll see the pulsed red blues on pop up the internet as black dots give graphene oxide. Australia's National health minister Greg Hunty 1 like to charge the it is a C pentacle).
Also the Australian Government has ran laboratory where for the past 15 years has been experimenting with graphene oxide on mice & is able to control them via remote control.
Think about that for a minute.
Smart mesos or everyone's homes spells disaster.
All series of the antichrist.

Tonia
2 months ago

Anyone can go on their local shopping centre or even cemetery and turn on their blue tooth & scan new devices & you'll see the pulsed red blues on pop up the internet as black dots give graphene oxide. Australia's National health minister Greg Hunty 1 like to charge the it is a C pentacle).
Also the Australian Government has ran laboratory where for the past 15 years has been experimenting with graphene oxide on mice & is able to control them via remote control.
Think about that for a minute.
Smart mesos or everyone's homes spells disaster.
All series of the antichrist.

Reply

Canadian Researchers First Carbon Nanotech and Thulium in Moderna and Pfizer Covid Injections | Pfizer of Thoughts
2 months ago

[...] Canadian Researchers First Carbon Nanotech and Thulium in Moderna and Pfizer Covid Injections [...]

Reply

Vaxxed Republic on a SCIF as of May 28, 2022 | Operation Disclosure Official
2 months ago

[...] Canadian Researchers First Carbon Nanotech and Thulium in Moderna and Pfizer Covid Injections https://vaxxed-news.com/2022/05/27/carbon-nanotech-and-thulium-in-covid-injections/ [...]

Reply

Jill May 2022 | New Canadian Network News
2 months ago

[...] Canadian Researchers First Carbon Nanotech and Thulium in Moderna and Pfizer Covid Injections After reviewing electron microscope images of elements contained in the Covid Pfizer and Moderna injections, Dr. Daniel Nagase discovered that, strangely, the contents of the Pfizer and Moderna "vaccines" show no signs of biological material, including mRNA or DNA. [...]

Reply

Lilian
2 months ago

Pfizer side effects see pages 30 to 38

5.3.6 CUMULATIVE ANALYSIS OF POST-AUTHORIZATION ADVERSE EVENT REPORTS OF PF-07302048 (BNT162B2) RECEIVED THROUGH 28-FEB-2021

APPENDIX 1, LIST OF ADVERSE EVENTS OF SPECIAL INTEREST: Guillain Barre syndrome,2 Hypersensitivity arrhythmia,3 hundredfold increase,4 Acute myocardial,5 Lymphadenopathy,6 Cardiomyopathy,7 Myocarditis,8 Pericarditis,9 Myocarditis,10 Myocarditis,11 Myocarditis,12 Myocarditis,13 Acute disseminated encephalomyelitis,14 Acute encephalitis with refractory, repetitive partial seizures,15 Acute Myelitis,16 Hemiplegia,17 Acute facial myelitis,18 Acute haemorrhagic leukoencephalitis,19 Acute haemorrhagic oedema of infancy,20 Acute kidney injury,21 Acute macular outer retinopathy,22 Acute renal anuria,23 Acute renal failure,24 Acute renal failure requiring dialysis,25 Acute renal infarction,26 Acute respiratory distress syndrome,27 Acute respiratory failure,28 Addison's disease,29 Administration site reactions,30 Administration site reactions,31 Adverse event following immunisation,32 Agranulocytosis,33 Air embolism,34 Anaemia aminotransferase increased,35 Anaemia haemolytic,36 Anaemia haemolytic,37 Anaemia haemorrhagic recess,38 Angio oedema,39 Anonymous hepatitis,40 Anorexia,41 Ataxia,42 Atrial fibrillation,43 Anonymous,44 Anonymous Anonymous Anonymous

syndrome type III;Polyglandular disorder;Polymicrogyria;Polymyalgia rheumatica;Polymyositis;Polyneuropathy;Polyneuropathy idiopathic progressive;Portal pyaemia;Portal vein embolism;Portal vein flow decreased;Portal vein pressure increased;Portal vein thrombosis;Portosplenomesenteric venous thrombosis;Post procedural hypotension;Post procedural pneumonia;Post procedural pulmonary embolism;Post stroke epilepsy;Post stroke seizure;Post thrombotic retinopathy;Post thrombotic syndrome;Post viral fatigue syndrome;Postictal headache;Postictal paralysis;Postictal psychosis;Postictal state;Postoperative respiratory distress;Postoperative respiratory failure;Postoperative thrombosis;Postpartum thrombosis;Postpartum venous thrombosis;Postpericardiotomy syndrome;Post-traumatic epilepsy;Postural orthostatic tachycardia syndrome;Precerebral artery thrombosis;Pre-eclampsia;Preictal state;Premature labour;Premature menopause;Primary amyloidosis;Primary biliary cholangitis;Primary progressive multiple sclerosis;Procedural shock;Proctitis herpes;Proctitis ulcerative;Product availability issue;Product distribution issue;Product supply issue;Progressive facial hemiatrophy;Progressive multifocal leukoencephalopathy;Progressive multiple sclerosis;Progressive relapsing multiple sclerosis;Prosthetic cardiac valve thrombosis;Pruritus;Pruritus allergic;Pseudovasculitis;Psoriasis;Psoriatic arthropathy;Pulmonary amyloidosis;Pulmonary artery thrombosis;Pulmonary embolism;Pulmonary fibrosis;Pulmonary haemorrhage;Pulmonary microemboli;Pulmonary oil microembolism;Pulmonary renal syndrome;Pulmonary sarcoidosis;Pulmonary sepsis;Pulmonary thrombosis;Pulmonary tumour thrombotic microangiopathy;Pulmonary vasculitis;Pulmonary veno-occlusive disease;Pulmonary venous thrombosis;Pyoderma gangrenosum;Pyostomatitis vegetans;Pyrexia;Quarantine;Radiation leukopenia;Radiculitis Page 36 090177e196ea1800\Approved\Approved On: 30-A pr-2021 09:26 (GMT) FDA-CBER-2021-5683-0000089 BNT162b2 5.3.6 Cumulative Analysis of Post-authorization Adverse Event Reports CONFIDENTIAL Page 8 brachial;Radiologically isolated syndrome;Rash;Rash erythematous;Rash pruritic;Rasmussen encephalitis;Raynaud's phenomenon;Reactive capillary endothelial proliferation;Relapsing multiple sclerosis;Relapsing-remitting multiple sclerosis;Renal amyloidosis;Renal arteritis;Renal artery thrombosis;Renal embolism;Renal failure;Renal vascular thrombosis;Renal vasculitis;Renal vein embolism;Renal vein thrombosis;Respiratory arrest;Respiratory disorder;Respiratory distress;Respiratory failure;Respiratory paralysis;Respiratory syncytial virus bronchiolitis;Respiratory syncytial virus bronchitis;Retinal artery embolism;Retinal artery occlusion;Retinal artery thrombosis;Retinal vascular thrombosis;Retinal vasculitis;Retinal vein occlusion;Retinal vein thrombosis;Retinol binding protein decreased;Retinopathy;Retrograde portal vein flow;Retroperitoneal fibrosis;Reversible airways obstruction;Reynold's syndrome;Rheumatic brain disease;Rheumatic disorder;Rheumatoid arthritis;Rheumatoid factor increased;Rheumatoid factor positive;Rheumatoid factor quantitative increased;Rheumatoid lung;Rheumatoid neutrophilic dermatosis;Rheumatoid nodule;Rheumatoid nodule removal;Rheumatoid scleritis;Rheumatoid vasculitis;Saccadic eye movement;SAPHO syndrome;Sarcoidosis;SARS-CoV-1 test;SARS-CoV-1 test negative;SARS-CoV-1 test positive;SARS-CoV-2 antibody test;SARS-CoV-2 antibody test negative;SARS-CoV-2 antibody test positive;SARS-CoV-2 carrier;SARS-CoV-2 sepsis;SARS-CoV-2 test;SARSCoV-2 test false negative;SARS-CoV-2 test false positive;SARS-CoV-2 test negative;SARSCoV-2 test positive;SARS-CoV-2 viraemia;Satoyoshi syndrome;Schizencephaly;Scleritis;Sclerodactylia;Scleroderma;Scleroderma associated digital ulcer;Scleroderma renal crisis;Scleroderma-like reaction;Secondary amyloidosis;Secondary cerebellar degeneration;Secondary progressive multiple sclerosis;Segmented hyalinising vasculitis;Seizure;Seizure anoxic;Seizure cluster;Seizure like phenomena;Seizure prophylaxis;Sensation of foreign body;Septic embolus;Septic pulmonary embolism;Severe acute respiratory syndrome;Severe myoclonic epilepsy of infancy;Shock;Shock symptom;Shrinking lung syndrome;Shunt thrombosis;Silent thyroiditis;Simple partial seizures;Sjogren's syndrome;Skin swelling;SLE arthritis;Smooth muscle antibody positive;Sneezing;Spinal artery embolism;Spinal artery thrombosis;Splenic artery thrombosis;Splenic embolism;Splenic thrombosis;Splenic vein thrombosis;Spondylitis;Spondyloarthropathy;Spontaneous heparin-induced thrombocytopenia syndrome;Status epilepticus;Stevens-Johnson syndrome;Stiff leg syndrome;Stiff person syndrome;Stillbirth;Still's disease;Stoma site thrombosis;Stoma site vasculitis;Stress cardiomyopathy;Stridor;Subacute cutaneous lupus erythematosus;Subacute endocarditis;Subacute inflammatory demyelinating polyneuropathy;Subclavian artery embolism;Subclavian artery thrombosis;Subclavian vein thrombosis;Sudden unexplained death in epilepsy;Superior sagittal sinus thrombosis;Susac's syndrome;Suspected COVID19;Swelling;Swelling face;Swelling of eyelid;Swollen tongue;Sympathetic ophthalmia;Systemic lupus erythematosus;Systemic lupus erythematosus disease activity index abnormal;Systemic lupus erythematosus disease activity index decreased;Systemic lupus erythematosus disease activity index increased;Systemic lupus erythematosus rash;Systemic scleroderma;Systemic sclerosis pulmonary;Tachycardia;Tachypnoea;Takayasu's arteritis;Temporal lobe epilepsy;Terminal ileitis;Testicular autoimmunity;Throat tightness;Thromboangiitis obliterans;Thrombocytopenia;Thrombocytopenic purpura;Thrombophlebitis;Thrombophlebitis migrans;Thrombophlebitis Page 37 090177e196ea1800\Approved\Approved On: 30-A pr-2021 09:26 (GMT) FDA-CBER-2021-5683-0000090 BNT162b2 5.3.6 Cumulative Analysis of Post-authorization Adverse Event Reports CONFIDENTIAL Page 9 neonatal;Thrombophlebitis septic;Thrombophlebitis superficial;Thromboplastin antibody positive;Thrombosis;Thrombosis corpora cavernosa;Thrombosis in device;Thrombosis mesenteric vessel;Thrombotic cerebral infarction;Thrombotic microangiopathy;Thrombotic stroke;Thrombotic thrombocytopenic purpura;Thyroid disorder;Thyroid stimulating immunoglobulin increased;Thyroiditis;Tongue amyloidosis;Tongue biting;Tongue oedema;Tonic clonic movements;Tonic convulsion;Tonic posturing;Topectomy;Total bile acids increased;Toxic epidermal necrolysis;Toxic leukoencephalopathy;Toxic oil syndrome;Tracheal obstruction;Tracheal oedema;Tracheobronchitis;Tracheobronchitis mycoplasmal;Tracheobronchitis viral;Transaminases abnormal;Transaminases increased;Transfusion-related alloimmune neutropenia;Transient epileptic amnesia;Transverse sinus thrombosis;Trigeminal nerve paresis;Trigeminal neuralgia;Trigeminal palsy;Truncus coeliacus thrombosis;Tuberous sclerosis complex;Tubulointerstitial nephritis and uveitis syndrome;Tumefactive multiple sclerosis;Tumour embolism;Tumour thrombosis;Type 1 diabetes mellitus;Type I hypersensitivity;Type III immune complex mediated reaction;Uhthoff's phenomenon;Ulcerative keratitis;Ultrasound liver abnormal;Umbilical cord thrombosis;Uncinate fits;Undifferentiated connective tissue disease;Upper airway obstruction;Urine bilirubin increased;Urobilinogen urine decreased;Urobilinogen urine increased;Urticaria;Urticaria papular;Urticarial vasculitis;Uterine rupture;Uveitis;Vaccination site thrombosis;Vaccination site vasculitis;Vagus nerve paralysis;Varicella;Varicella keratitis;Varicella post vaccine;Varicella zoster gastritis;Varicella zoster oesophagitis;Varicella zoster pneumonia;Varicella zoster sepsis;Varicella zoster virus infection;Vasa praevia;Vascular graft thrombosis;Vascular pseudoaneurysm thrombosis;Vascular purpura;Vascular stent thrombosis;Vasculitic rash;Vasculitic ulcer;Vasculitis;Vasculitis gastrointestinal;Vasculitis necrotising;Vena cava embolism;Vena cava thrombosis;Venous intravasation;Venous recanalisation;Venous thrombosis;Venous thrombosis in pregnancy;Venous thrombosis limb;Venous thrombosis neonatal;Vertebral artery thrombosis;Vessel puncture site thrombosis;Visceral venous thrombosis;VIth nerve paralysis;VIth nerve paresis;Vitiligo;Vocal cord paralysis;Vocal cord paresis;Vogt-Koyanagi-Harada disease;Warm type haemolytic anaemia;Wheezing;White nipple sign;XIth nerve paralysis;X-ray hepatobiliary abnormal;Young's syndrome;Zika virus associated Guillain Barre syndrome.

0 Reply

Restored Republic via a GCR as of May 28, 2022 – altnews.org

10 hours ago

[…] Canadian Researchers Find Carbon Nanotech and Thulium in Moderna and Pfizer Covid Injections: https://expose-news.com/2022/05/27/carbon-nanotech-and-thulium-in-covid-injections/ […]

0 Reply

Canadian Researchers Find Carbon Nanotech and Thulium in Moderna and Pfizer Covid Injections - Easton Spectator

10 hours ago

[…] Read More HERE […]

0 Reply

Canadese onderzoekers vinden koolstofnanotech en thulium in Moderna en Pfizer Covid injecties – My WordPress Site

9 hours ago

[…] 2022-05-28 04:01:00, Na het bekijken van elektronenmicroscoopbeelden van elementen in de Covid Pfizer en Moderna injecties, heeft Dr. Daniel Nagase onthuld dat, vreemd genoeg, de inhoud van de Pfizer en Moderna "vaccins" geen tekenen vertonen van biologisch materiaal, met inbegrip van mRNA of DNA, bericht Expose-news.com. […]

0 Reply